

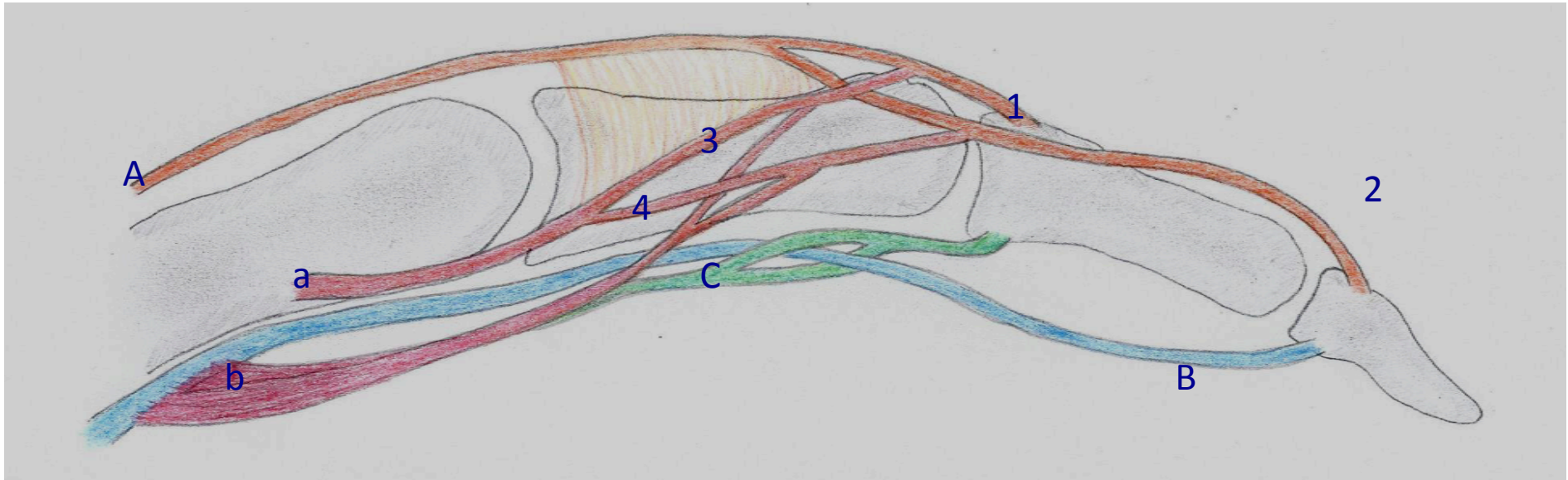


EFSHT Cheat Card

The extrinsic and intrinsic muscle group - Function

Name	Function
M.ext.digitorum comm. (N.rad.)	Extends the phalanges proximales and indirectly the entire hand
M.flex.dig.prof. (N.uln. for ulnar side) (N.med. for radial side)	Flexes IP joints, especially the phalanges distales
M.flex.dig.superf. (N.med.)	Flexes phalanges mediae of the 4 fingers
Mm. Interossei (N.uln.)	Flexes digiti 2-5 at MCP joints Extend the two phalanges distales at the corresponding IP joints
Mm. Lumbricales (N.med.: I, II) (N.uln.: III, IV)	Flexes the MCP joints Extends the two phalanges distales

Intrinsic and Extrinsic muscles - Anatomy



Extrinsic group

Extensor digitorum communis (**A**)
Central band of extensor tendon (**1**)
Collateral band of extensor tendon (**2**)
Flexor digitorum profundus (**B**)
Flexor digitorum superficialis (**C**)

Intrinsic group

Interosseus tendon (**a**)
Medial band of intrinsic tendon (**3**)
Lateral band of intrinsic tendon (**4**)
Lumbrical muscle and tendon (**b**)